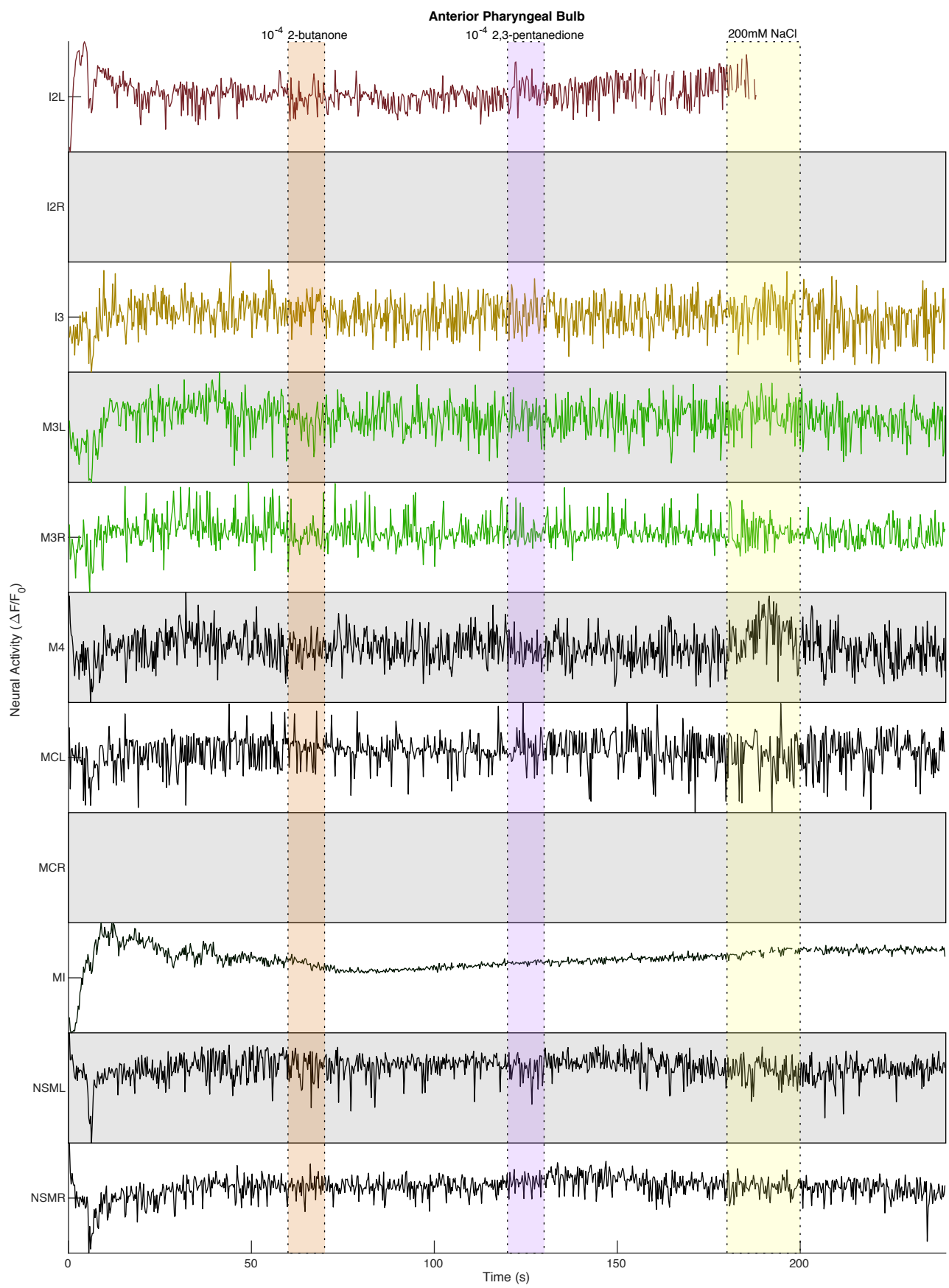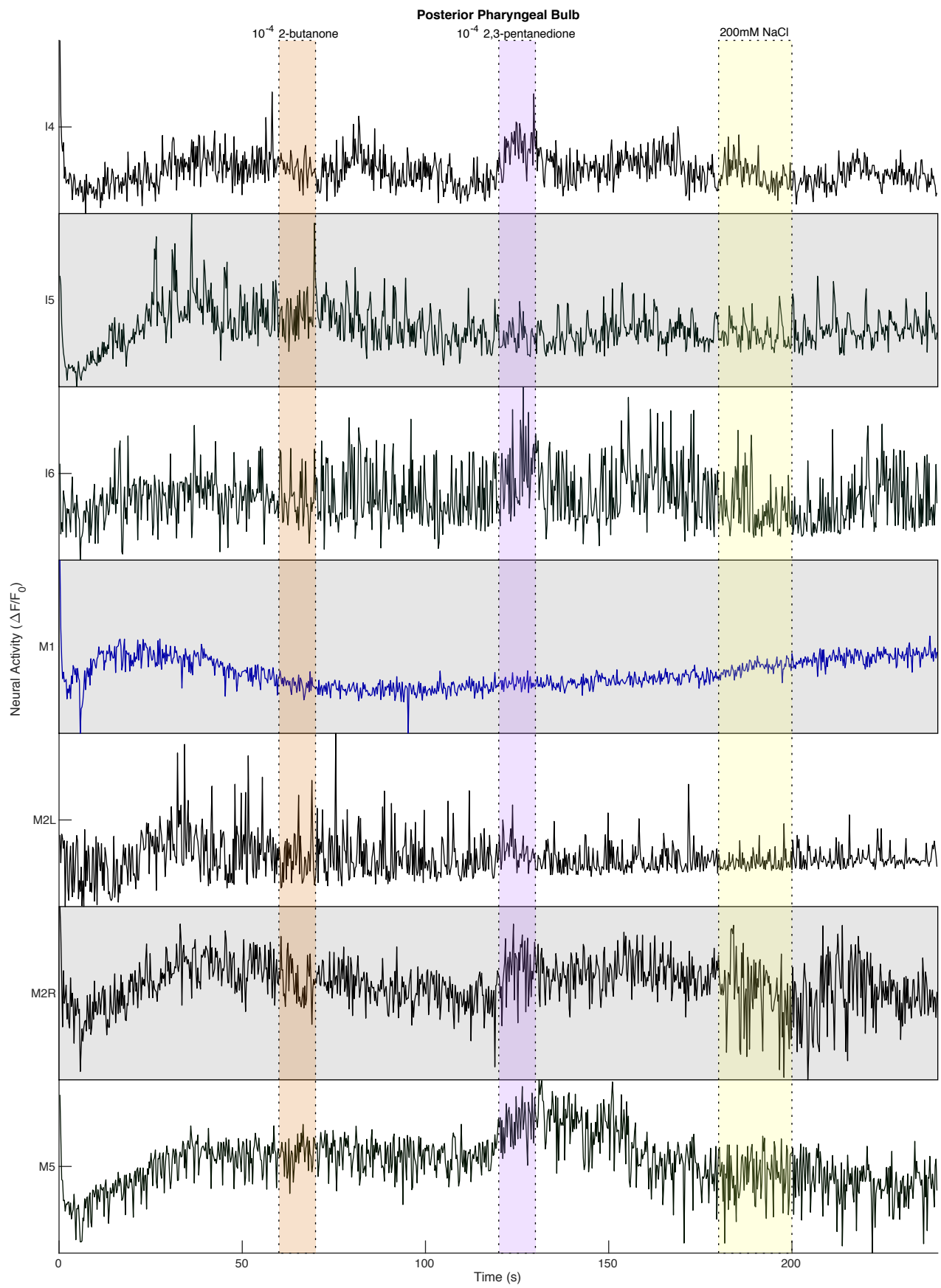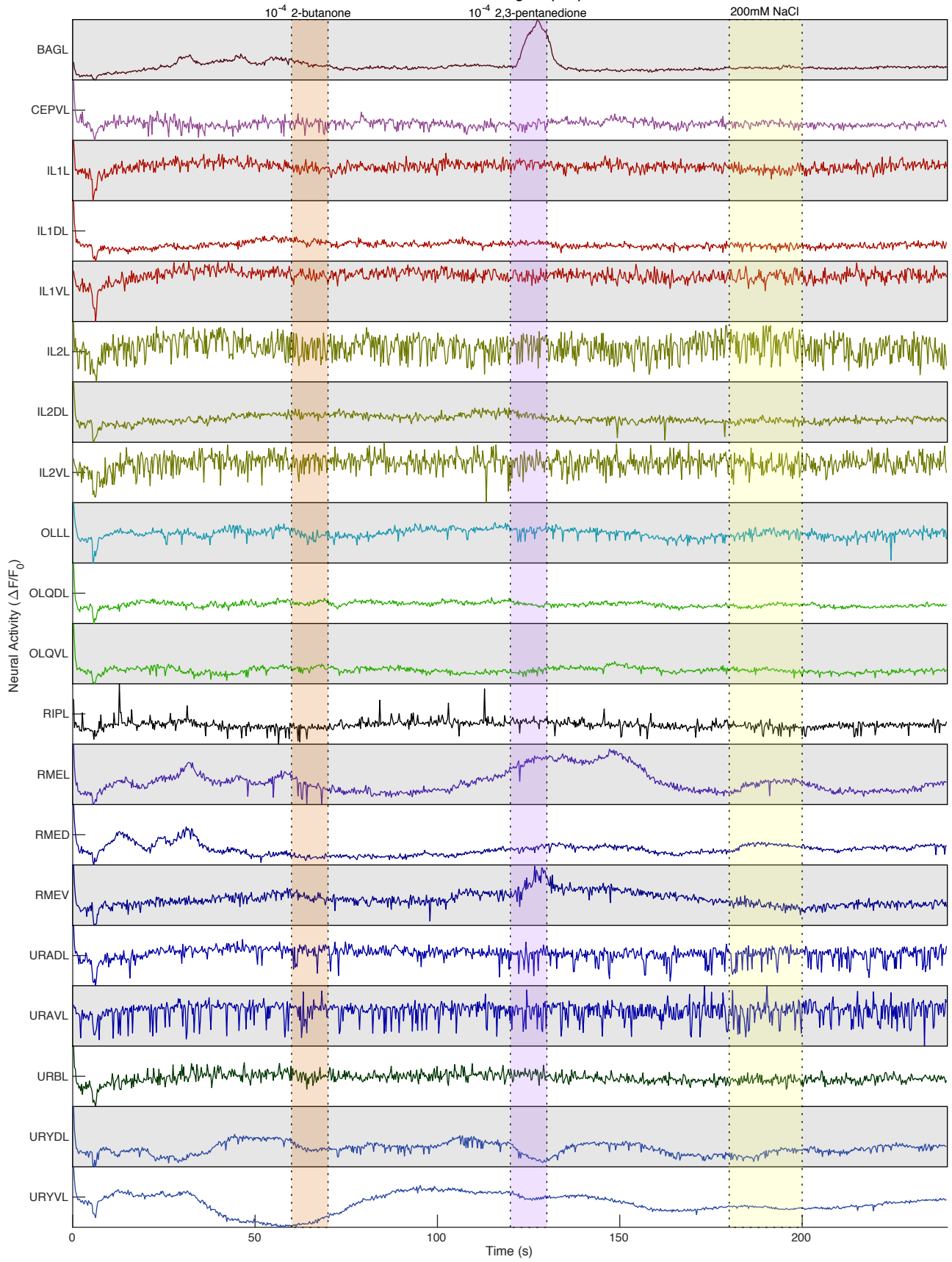
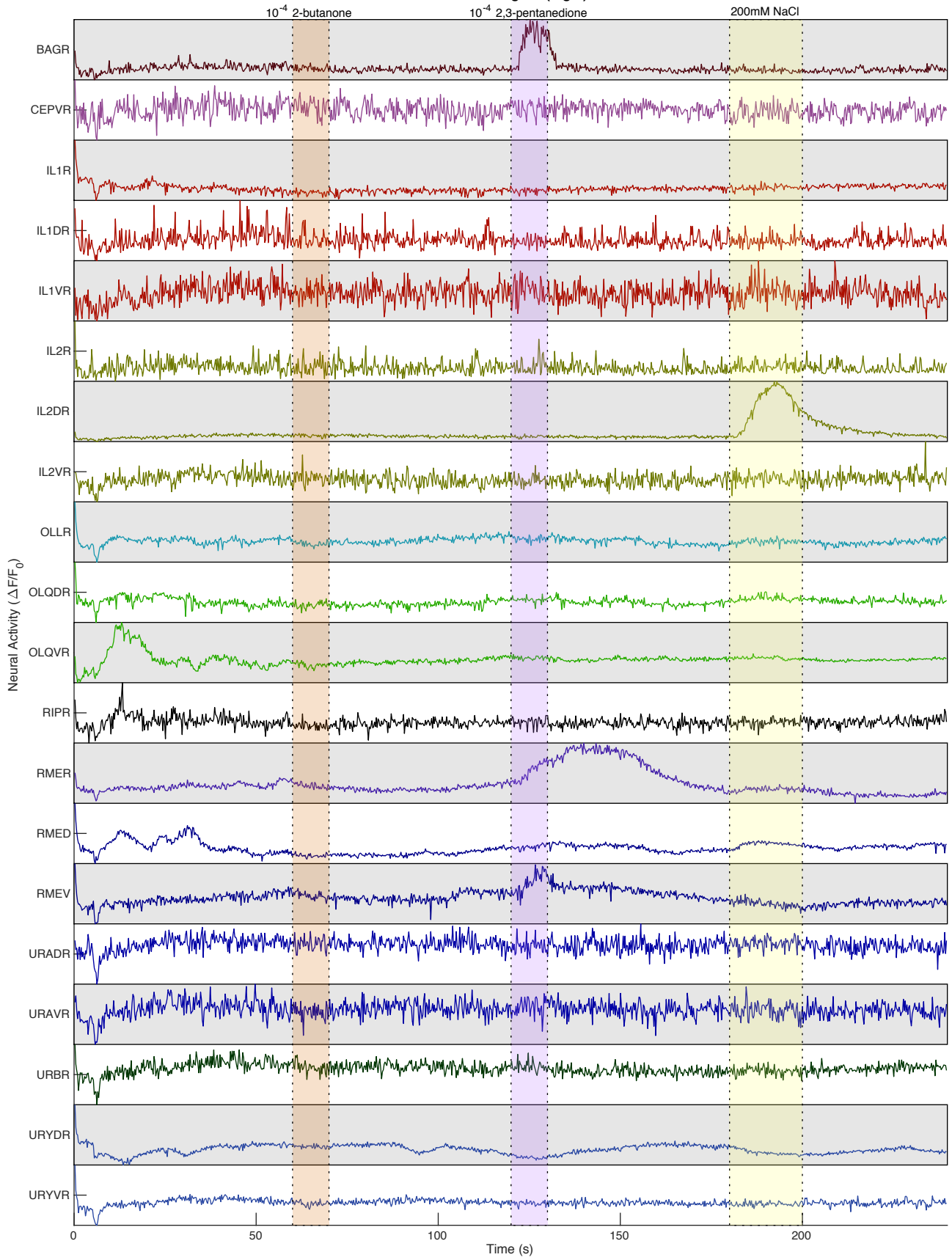
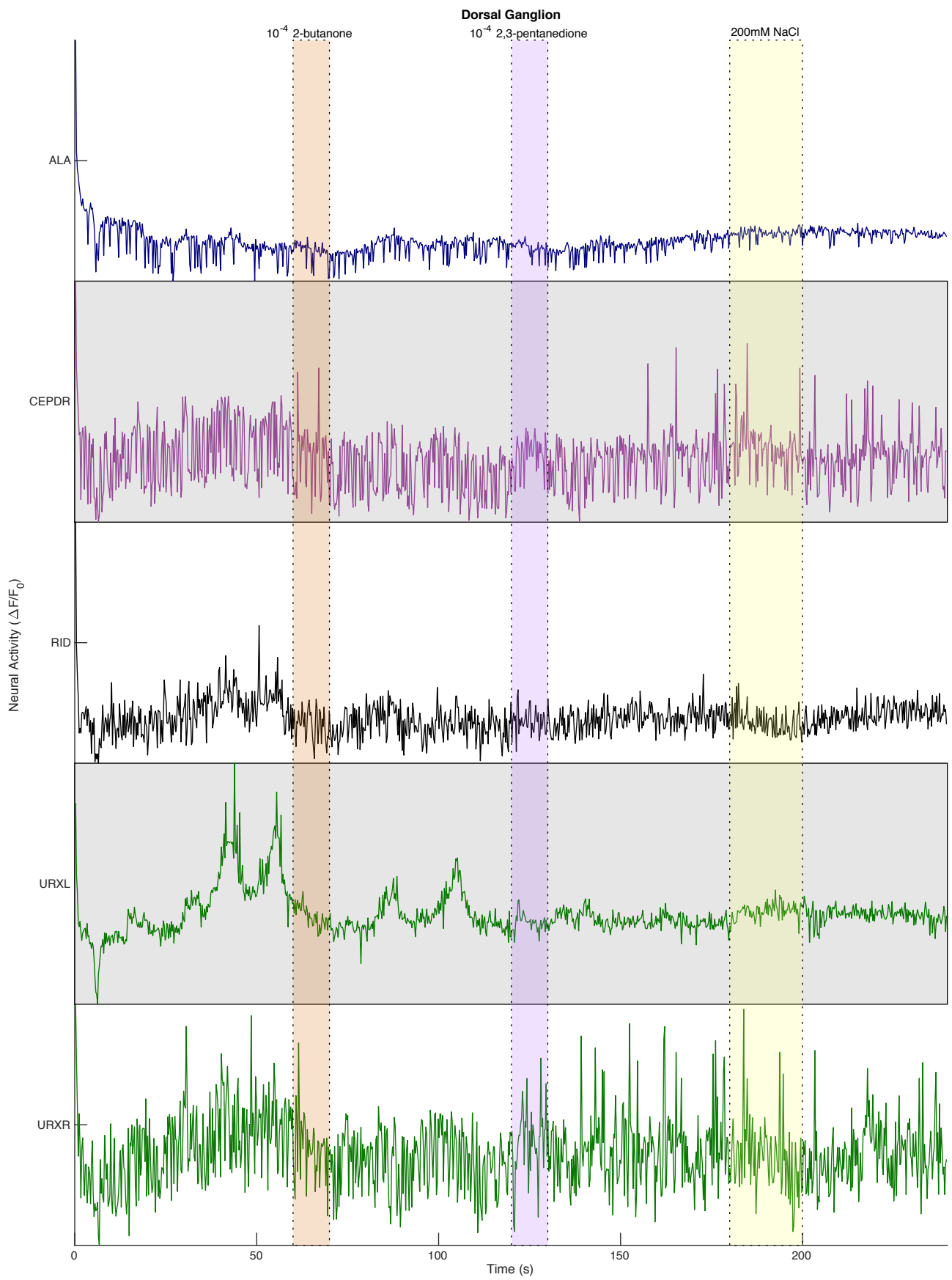


Anterior Ganglion (Left)

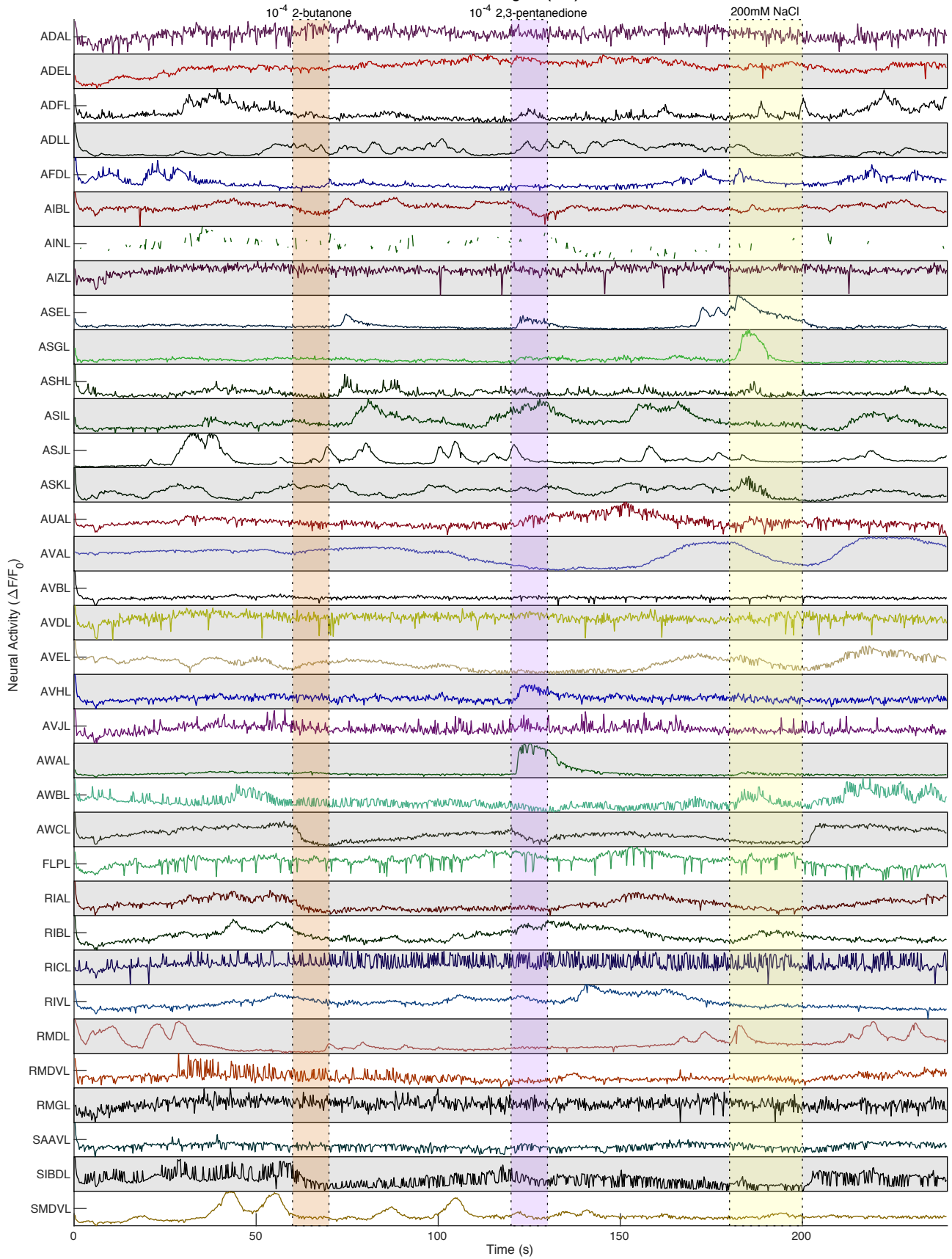


Anterior Ganglion (Right)

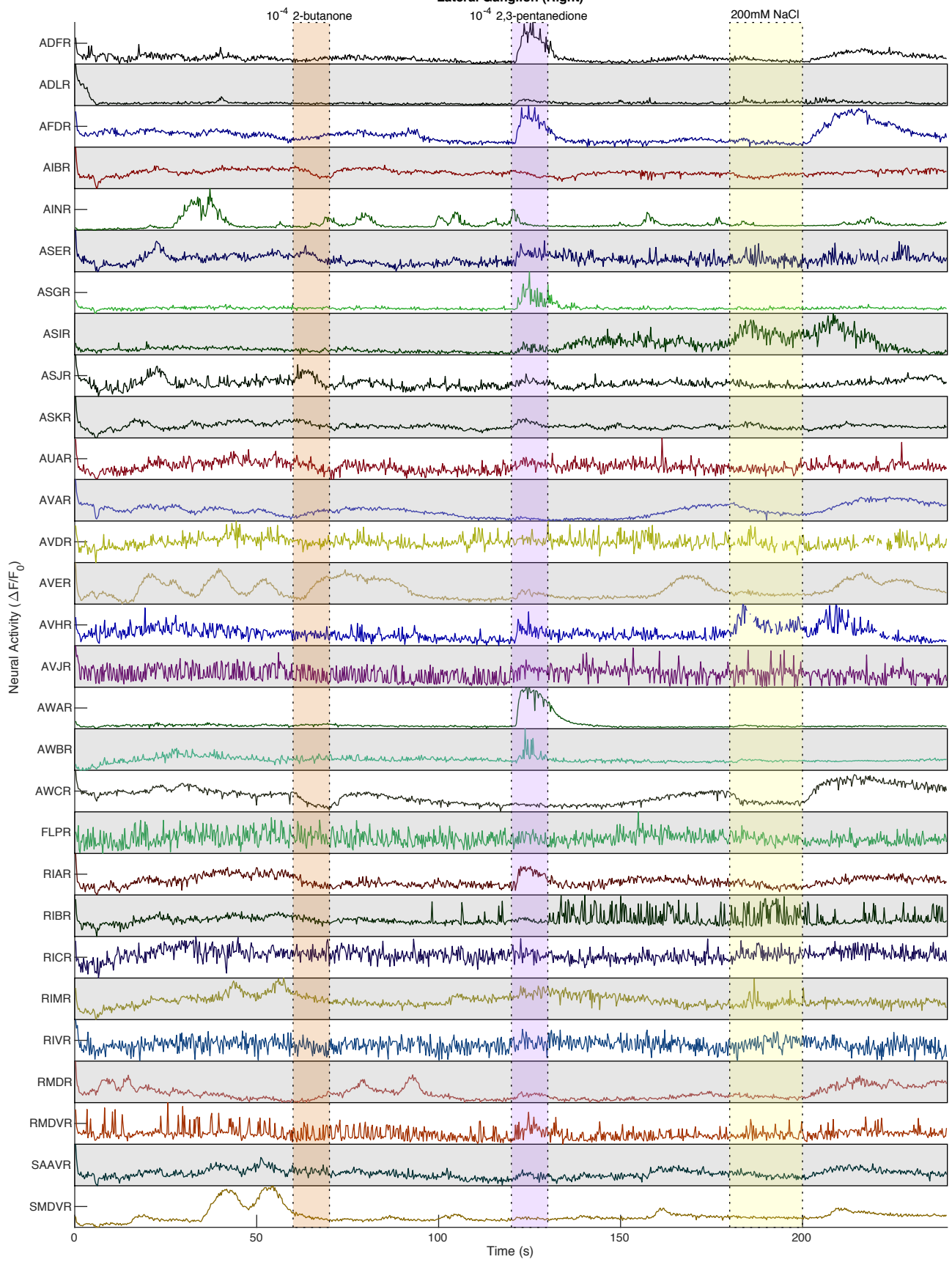


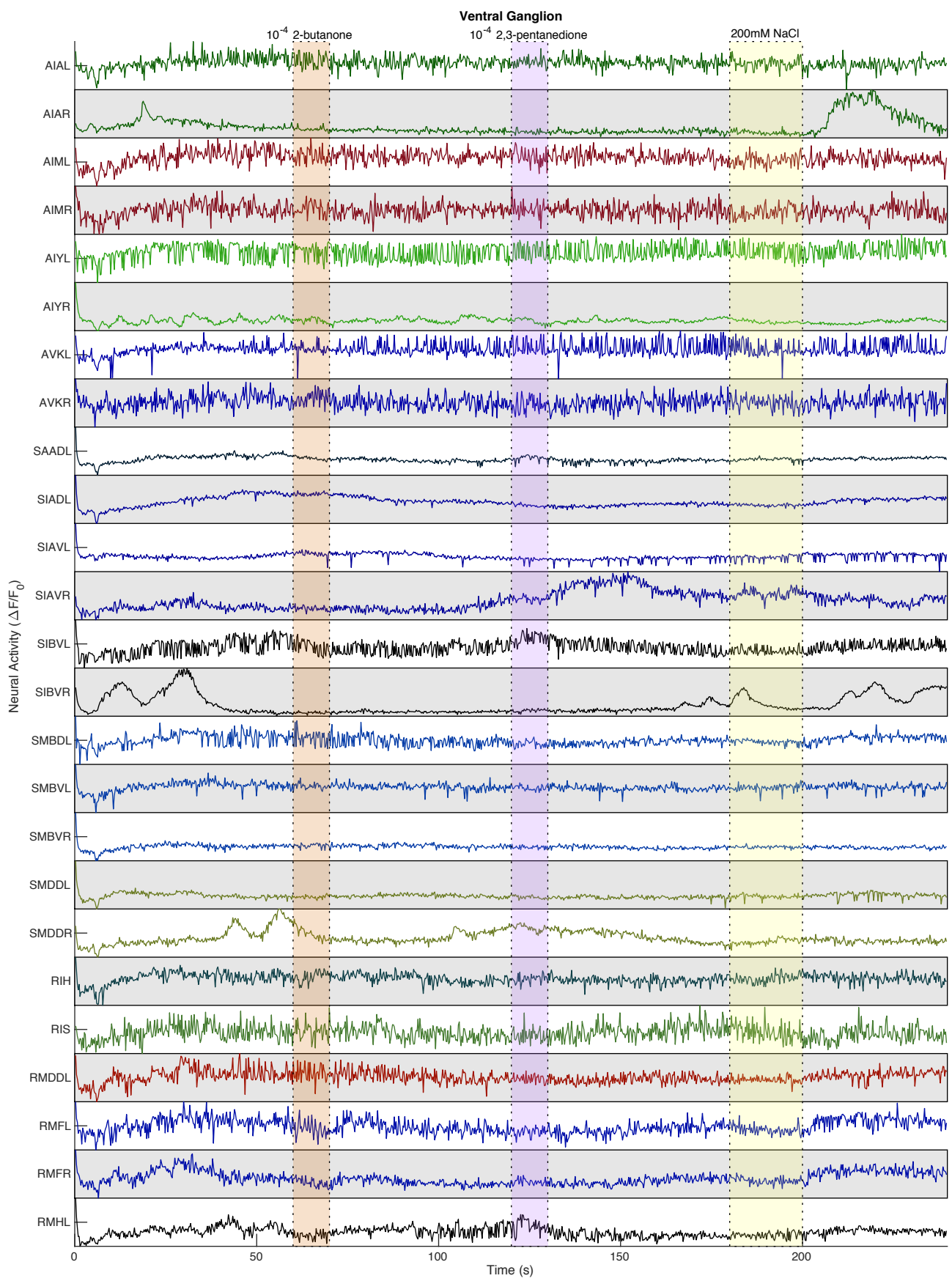


Lateral Ganglion (Left)



Lateral Ganglion (Right)





Retrovesicular Ganglion

