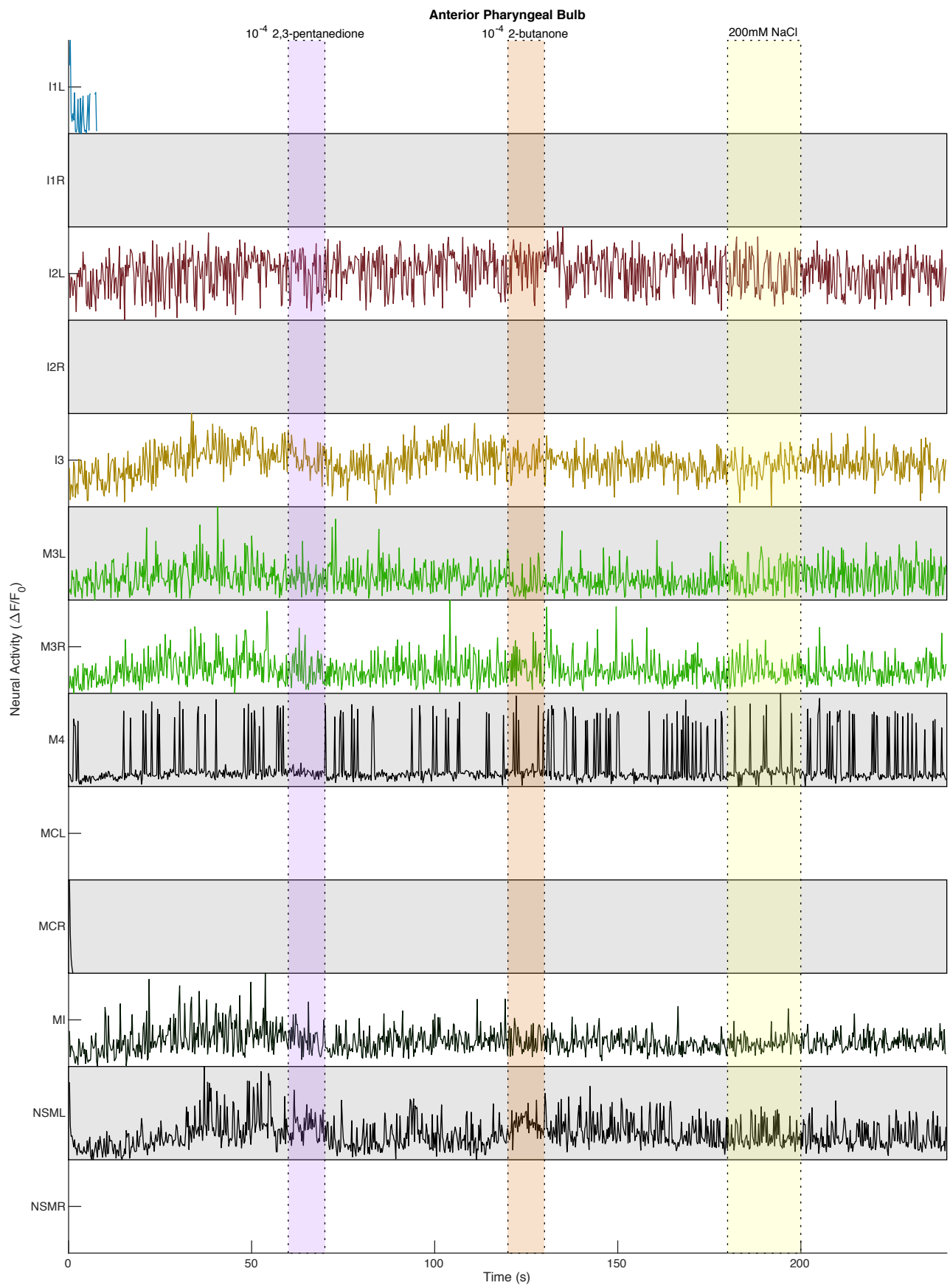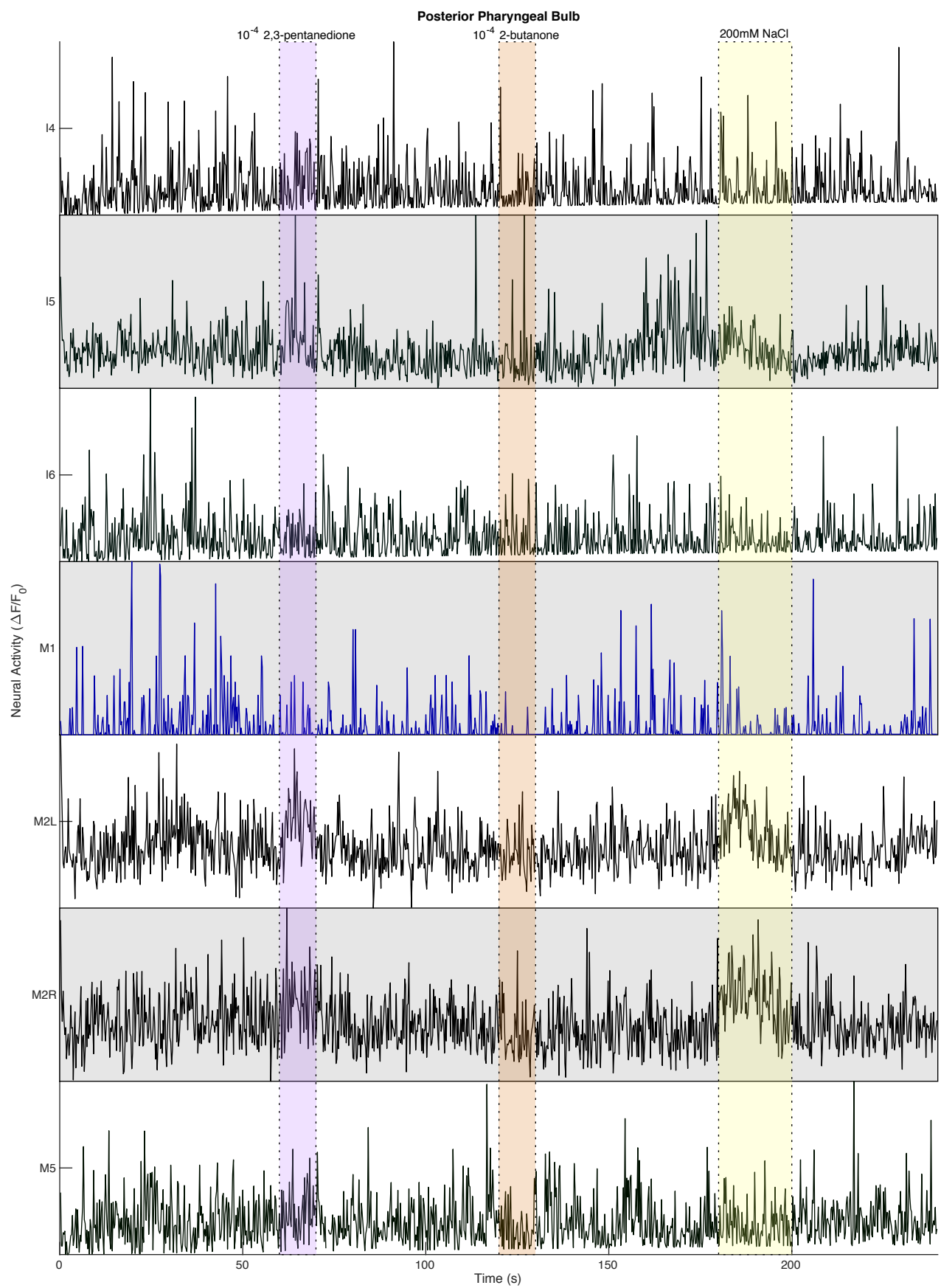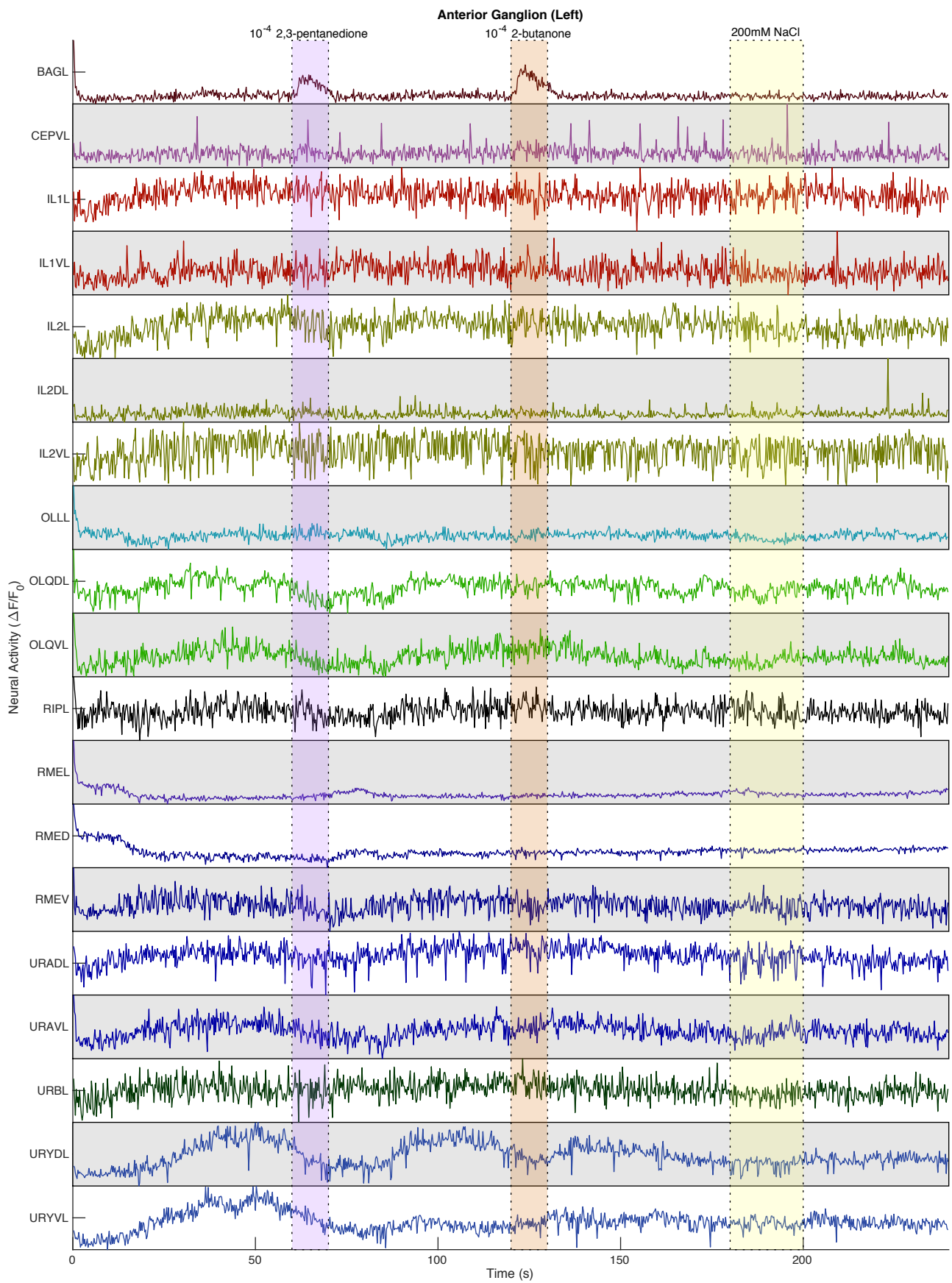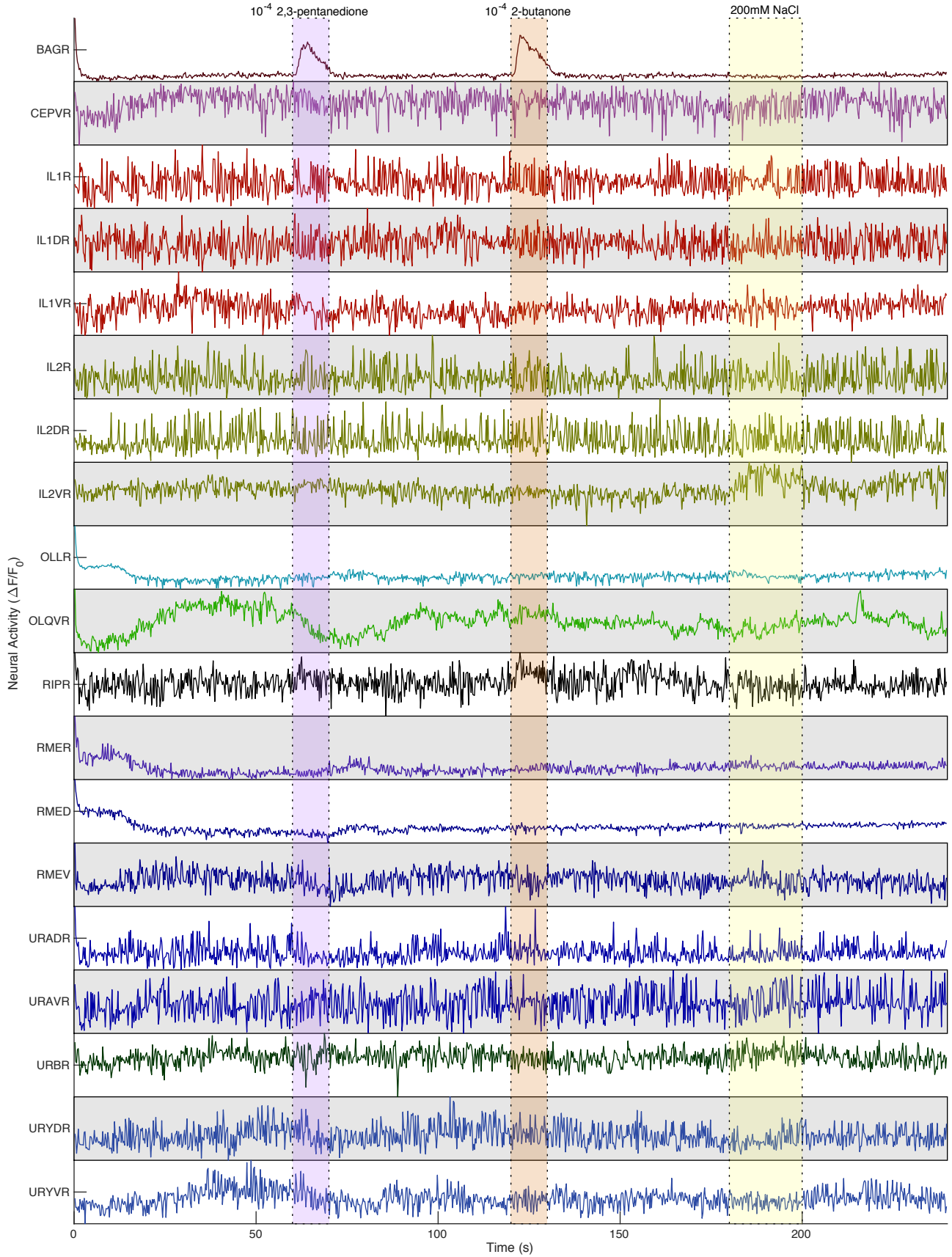
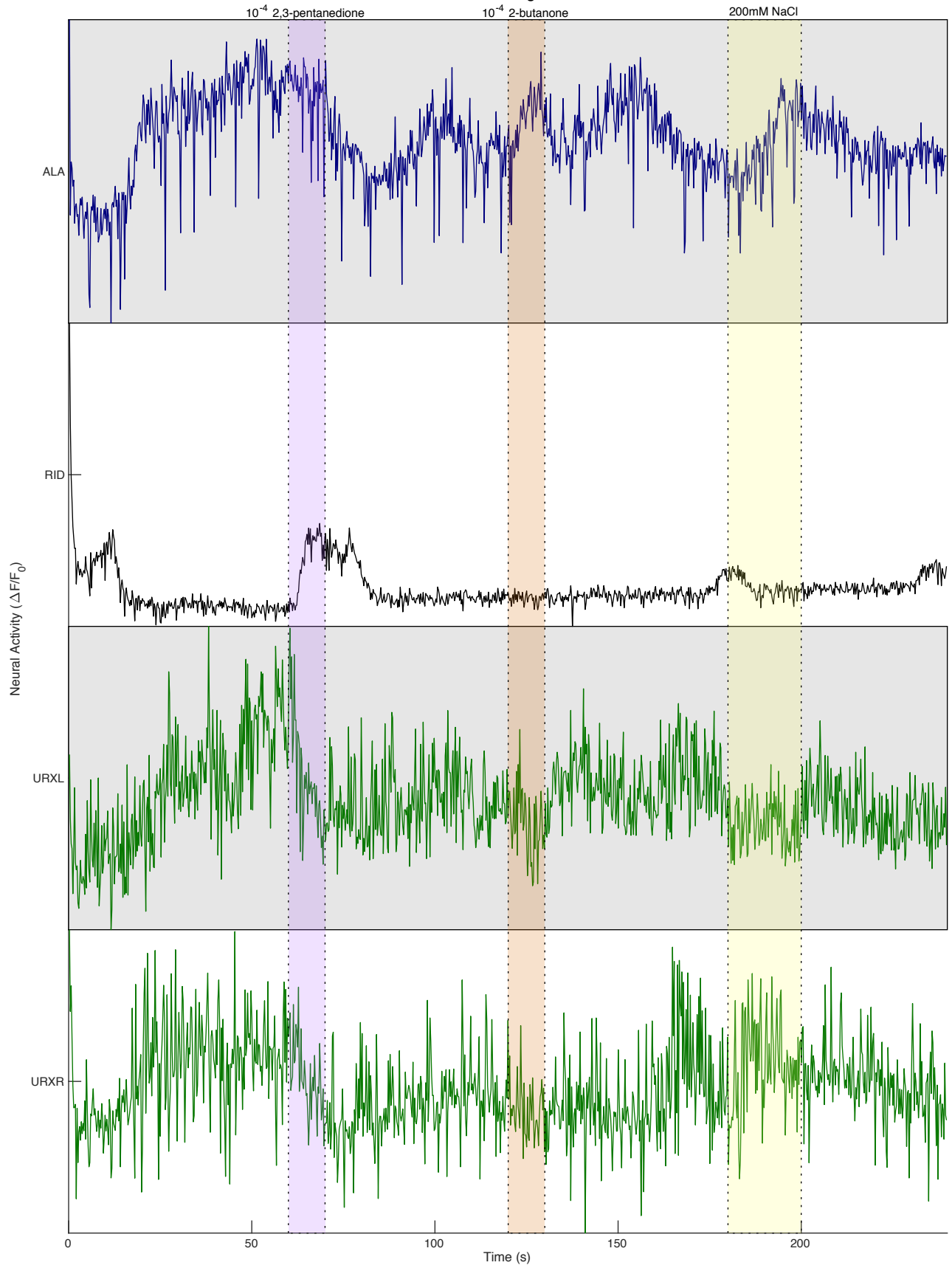
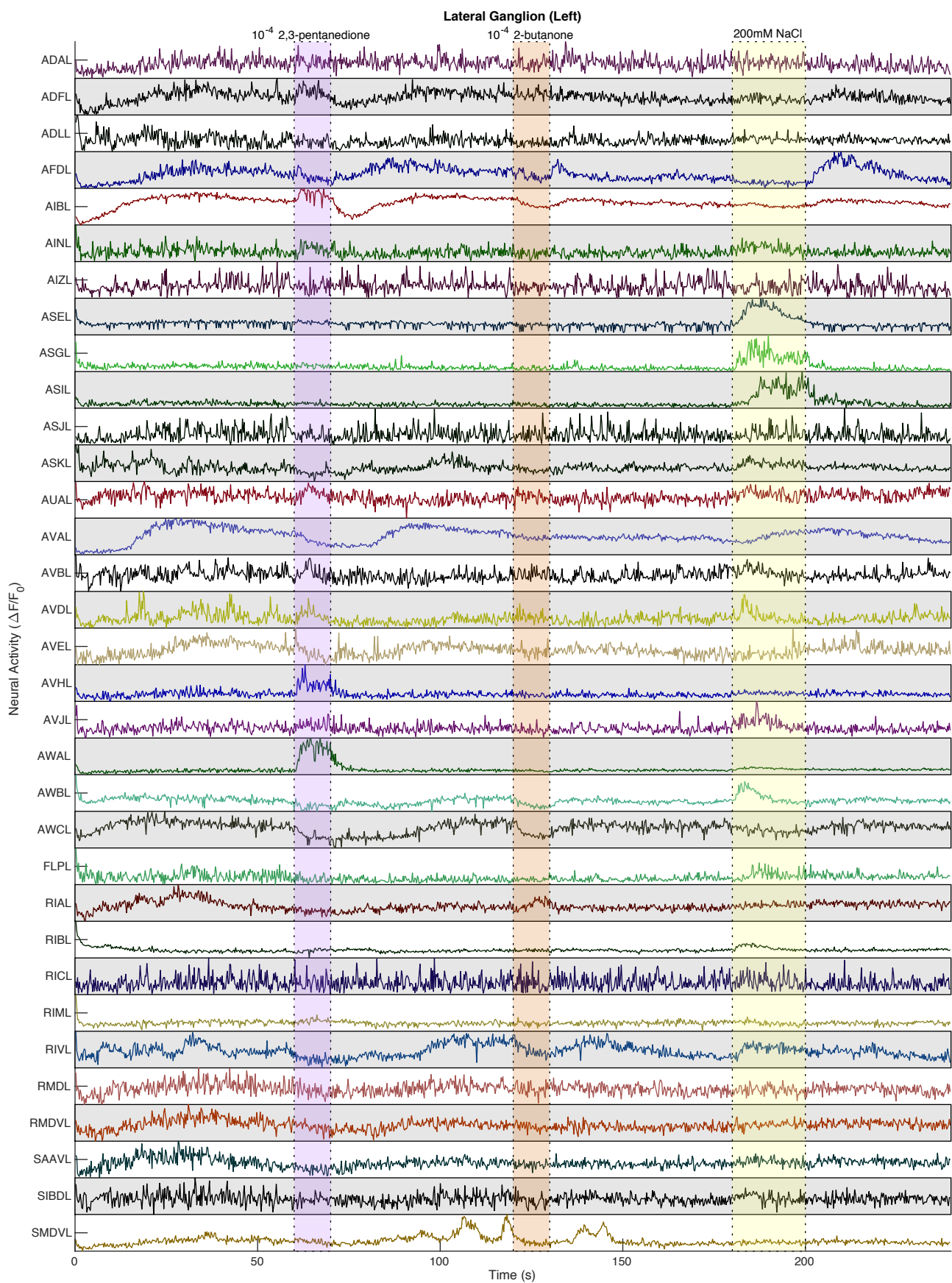


Anterior Ganglion (Right)

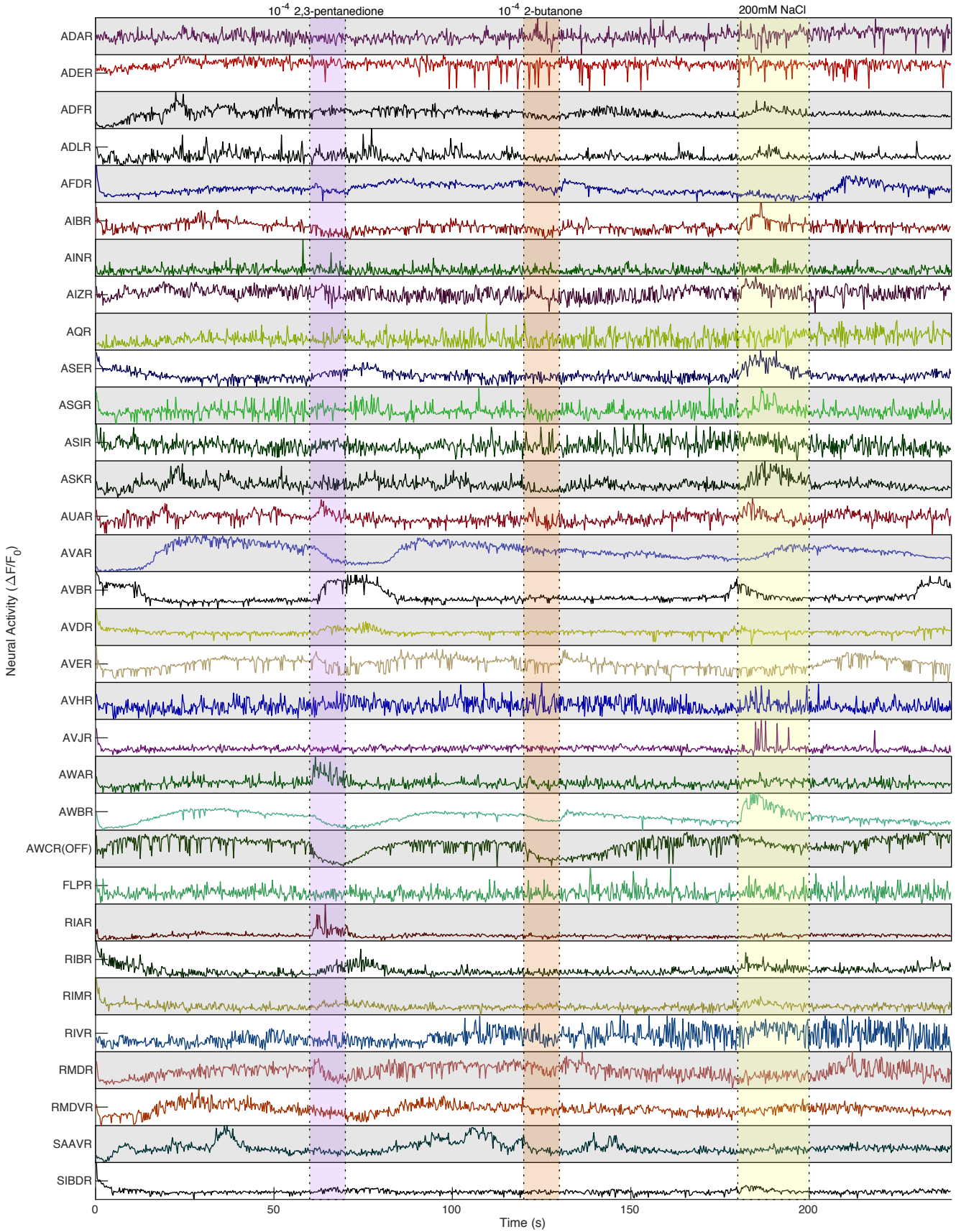


Dorsal Ganglion





Lateral Ganglion (Right)



Ventral Ganglion

